

## Links

Department of Environment and Conservation

[www.env.gov.nl.ca/env/](http://www.env.gov.nl.ca/env/)

Canadian Cooperative Wildlife Health Center

[www.ccwhc.ca](http://www.ccwhc.ca)

## Photo Credits

(Figures 2-4)

Ontario Ministry of Natural Resources

For more information, please contact your Regional Veterinarian, your local Conservation Officer or the Animal Health Division.

Other information pamphlets are available online from the Department of Natural Resources at:

[www.nr.gov.nl.ca/agric/](http://www.nr.gov.nl.ca/agric/)

Publication: DS 04-009  
Last Revised: March 2010



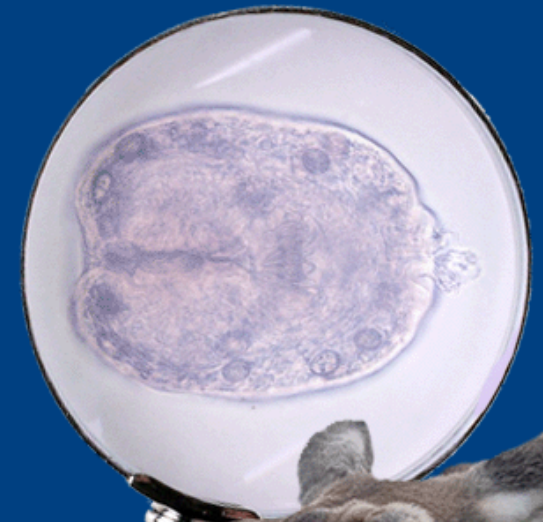
Department of Natural Resources  
Animal Health Division  
P.O. Box 7400  
St. John's, NL  
A1E 3Y5

t 709.729.6879  
f 709.729.0055

[animalhealthdivision@gov.nl.ca](mailto:animalhealthdivision@gov.nl.ca)



# Parasites Of Moose: Tapeworm Cysts



## Introduction

All wild animals carry diseases. In some cases, these might be of concern if they can spread to humans or domestic animals. In other cases, they might be of interest if they impact on the health of our wild herds, or simply if they have been noticed by hunters and you would like to know more.

This pamphlet is one of a series produced on the common diseases of wildlife in Newfoundland and Labrador and covers the cyst form of two common tapeworm parasites. The first exists on both the Island of Newfoundland and in Labrador and has no known public health importance, while the second (hydatid disease) is so far only reported in Labrador and can be a cause of human illness.

## Life Cycle of Tapeworm Cysts

Tapeworms are a type of parasite that usually require two different hosts - a predator species and a prey species - to complete their life cycle (Figure 1).

The common predators are wolves (Labrador), coyotes, bears, lynx and dogs (depending on the parasite); while the prey can be moose, caribou or domestic animals, such as sheep and cattle. Humans can become an accidental host as will be described.

The adult stage of the parasite is called the tape and lives in the intestines of the predator, or final host. This tape can be very long or hardly visible depending on the parasite. When visible, it looks like a long flat measuring tape.

It has a head (or scolex) which attaches onto the wall of the intestine by way of a ring of hooks and 4 suckers (Figure 4). This allows the parasite to live off the food in the animal's gut.

This adult stage releases eggs into the gut which leave in the feces and contaminate the ground and possibly also the animal's fur. The eggs are eaten by the moose and develop in the body into a cyst form. As it does not produce any eggs, it is called the intermediate stage.

These cysts can be very small or large depending on the species of parasite and the part of the body they occupy. They either stay inactive in the body until the prey is eaten by the predator, or else they may become neutralized by the body's immune system. Once in the predator again, the cyst is activated and the parasite develops into the tape form to continue the cycle.

The cyst looks different depending on the parasite. For *Taenia krabbei* (in muscle, Figure 2), it is small with almost no fluid in it. For *Echinococcus granulosus* (liver or lungs, Figure 3), the cyst can be golf ball size with a lot of fluid.

### *Taenia krabbei*

The cyst can be found in the muscles and heart of moose and occasionally in the caribou. It was not very common on the Island of Newfoundland until the early 1980's. First reports appeared on the southwest coast, then progressed to the east.



Figure 1: Predator – Prey Life Cycle.



Figure 2: *Taenia krabbei* cyst in moose steak.

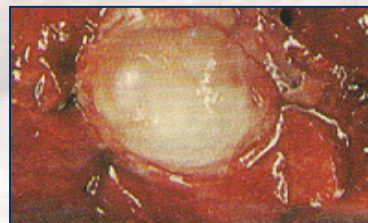


Figure 3: Hydatid cyst in a lung.

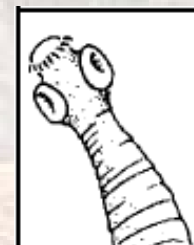

Figure 4: Scolex of the Adult Tapeworm.

Sometimes there are only a few cysts in the muscle that can be easily picked out, while other times there are hundreds visible. They are yellowish and a bit bigger than a grain of rice. There is no direct risk to human health from eating the cooked meat. There is no need to reject or waste a moose carcass because of a few cysts that can be easily removed. It is understandable, though, that if there are large numbers visible, the meat may not look appetizing.

### *Echinococcus granulosus* (Hydatid Disease)

This cyst is found in the lungs and liver of Labrador moose and caribou. If there are a lot of cysts in the lung, it may decrease the animal's stamina particularly when chased by a predator. Its importance increases, though, since it can also harm people.

If infected lungs or liver are fed to dogs, they can develop the adult tape which will shed eggs that can stick to the dog's fur. If someone then pets the dog and touches their own mouth, they can infect themselves with this parasite. It can also be picked up by handling contaminated pelts (such as wolf). In humans, this cyst can develop in many parts of the body, sometimes causing serious illness.

In areas where infected wolves (or dogs) can feed on domestic sheep, there is a possibility for the disease to establish a completely domestic cycle (dog to sheep).