

Links

OMAFRA

<http://www.omafra.gov.on.ca/english/livestock/alternat/furfarm.htm>

For more information, please contact your Regional Veterinarian, the Non-Ruminant Specialist or the Animal Health Division.

Other information pamphlets are available online from the Department of Natural Resources at:

www.nr.gov.nl.ca/agric/

Publication: VS 05-002
Last Revised: March 2010



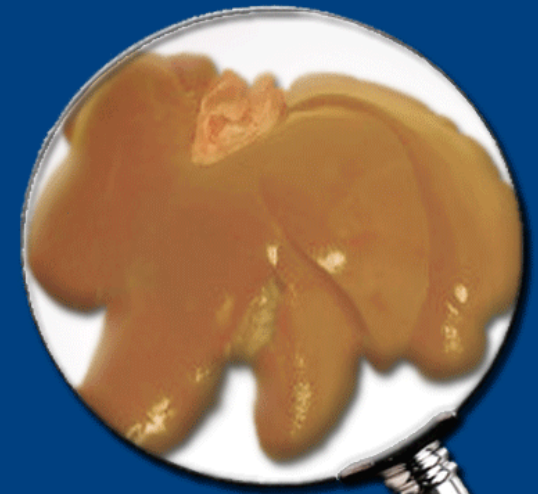
Department of Natural Resources
Animal Health Division
P.O. Box 7400
St. John's, NL
A1E 3Y5

t 709.729.6879
f 709.729.0055

animalhealthdivision@gov.nl.ca



Fatty Liver Syndrome And Yellow Fat Disease



Introduction

Fatty Liver Syndrome and Yellow Fat Disease are two disease entities which have been diagnosed on a number of ranches in this province, specifically in Blue Fox. Silver Fox on the same ranch, diet, and management systems have remained unaffected. This pamphlet provides information on these conditions and ways in which they can be prevented.

Fatty Liver Syndrome (*Hepatic Lipidosis*)

Hepatic Lipidosis is a disease condition resulting in abnormal accumulation of fat in the fox's liver cells. This causes varying degrees of liver failure in affected animals. Overweight fox are particularly predisposed to this condition.

Typically, a ranch housing Silver and Blue Fox and feeding the same diet to both species, would come through the breeding period for the Silvers without incident. Problems would first appear when the Blues started to come in heat. Several of the Blues would go off feed, show poor or no heats and suffer weight loss. Closer examination of these fox would reveal signs of jaundice (a yellow discolouration of the gums and the whites of the eyes) and muscle loss. The abdominal fat pad is, however, often still present giving a pot bellied appearance. Many animals would remain "off feed" for 3 weeks or more. Most fox recover after several weeks, but some die.

Reproductive performance on the ranch is impaired as a result of poor or no heat signs and reduced litter size. On post mortem examination, all the body fat appears yellow in colour and the liver is enlarged, fatty and has an "orange peel" appearance to its surface.

This condition results from an upset in the fox's metabolism, but the actual mechanism is not fully understood. The liver cells seem unable to keep up with the body's requirements to convert fats into a different form. Once the animal has gone "off feed," a vicious circle is set up. The animal's liver is further overloaded, as the fox is not eating and now needs to break down its own body fat reserves to stay alive.

Once the liver is affected, the disease is difficult to treat. Treatment regimes for this disease in other species involve intravenous fluids and force feeding a special diet through a tube implanted in the animal's stomach. Not a very practical proposition in fox.

This disease can be prevented by the proper conditioning of Blue Fox. It is imperative that this be initiated in August as it seems to be very hard to reduce the weight of Blue Fox in the fall and winter. The inclusion of a Choline/Methionine supplement, designed for poultry, to the diet may help.

Yellow Fat Disease

As with Fatty Liver Syndrome, Blue Fox seem to be particularly susceptible to **Yellow Fat Disease**. This is in part because the eating habits and physiology of this species is different from Silvers. Yellow Fat Disease results in similar symptoms to Hepatic Lipidosis except that the chances of spontaneous recovery are much less likely. This is due to the fact that in Yellow Fat Disease, many of the cells in the liver and fat reserves actually die.

Yellow Fat Disease can result from a number of factors:

1. The inclusion of rancid fat in the diet. Remember that fat can go rancid even while frozen. This is particularly true of marine fats such as seal. When fat goes rancid, it uses all the Vitamin E in the diet.
2. Blue Fox fed large amounts of unsaturated fat (vegetable oil in particular) are more prone to Yellow Fat Disease. Unsaturated fats are those which are liquid at room temperature. In Blue Fox, these fats are often absorbed, undigested from the intestine and stored in the body where they go rancid in the absence of sufficient Vitamin E.

3. A deficiency of Vitamin E in the diet. Many ranchers are supplementing their Blue Fox rations with Vitamin E, but be careful to follow the manufacturer's premix instructions and do not use outdated product. The recommended rate is 50,000 international units (IU) of Vitamin E per ton of feed.

Some fox with Yellow Fat Disease will show abscess formation, particularly in the lumbar area (lower back), resulting in large patches of skin sloughing off the back. On post mortem, apart from the obvious yellow fat, some animals show an abnormal hardness and a white colour of the fat in the lumbar region. Watch for this at pelting time.

Yellow Fat Disease can be prevented by the inclusion of a Vitamin E premix in the diet and careful selection of both the quality and type of fat to be added to the ration.

If you suspect you have encountered either of these conditions on your ranch in the past, please consult your Regional Veterinarian for advice **BEFORE** breeding season.